

# Stroke

American Stroke  
Association<sup>SM</sup>

JOURNAL OF THE AMERICAN HEART ASSOCIATION

A Division of American  
Heart Association



**Restenosis After Carotid Angioplasty, Stenting, or Endarterectomy in the  
Carotid and Vertebral Artery Transluminal Angioplasty Study (CAVATAS)**  
Dominick J.H. McCabe, Anthony C. Pereira, Andrew Clifton, J. Martin Bland, Martin  
M. Brown and on behalf of the CAVATAS Investigators

*Stroke* 2005;36;281-286; originally published online Jan 13, 2005;

DOI: 10.1161/01.STR.0000152333.75932.fe

Stroke is published by the American Heart Association, 7272 Greenville Avenue, Dallas, TX 75214

Copyright © 2005 American Heart Association. All rights reserved. Print ISSN: 0039-2499. Online  
ISSN: 1524-4628

The online version of this article, along with updated information and services, is  
located on the World Wide Web at:

<http://stroke.ahajournals.org/cgi/content/full/36/2/281>

Subscriptions: Information about subscribing to Stroke is online at

<http://stroke.ahajournals.org/subscriptions/>

Permissions: Permissions & Rights Desk, Lippincott Williams & Wilkins, a division of Wolters  
Kluwer Health, 351 West Camden Street, Baltimore, MD 21202-2436. Phone: 410-528-4050. Fax:  
410-528-8550. E-mail:

[journalpermissions@lww.com](mailto:journalpermissions@lww.com)

Reprints: Information about reprints can be found online at

<http://www.lww.com/reprints>

# Restenosis After Carotid Angioplasty, Stenting, or Endarterectomy in the Carotid and Vertebral Artery Transluminal Angioplasty Study (CAVATAS)

Dominick J.H. McCabe, PhD; Anthony C. Pereira, MD; Andrew Clifton FRCR; J. Martin Bland, PhD; Martin M. Brown, FRCP; on behalf of the CAVATAS Investigators

**Background and Purpose**—Carotid and Vertebral Artery Transluminal Angioplasty Study (CAVATAS) patients with carotid stenosis were randomized between endovascular treatment and endarterectomy. The rates of residual severe stenosis and restenosis and their contribution to recurrent symptoms was unclear.

**Methods**—Endovascular patients were treated by balloon angioplasty alone (88%) or stenting (22%). Patches were used in 63% of endarterectomy patients. Carotid stenosis was categorized as mild (0% to 49%), moderate (50% to 69%), severe (70% to 99%), or occluded, using standardized Doppler ultrasound criteria at the examination closest to 1 month (n=283) and 1 year (n=347) after treatment. Recurrent cerebrovascular symptoms during follow-up were analyzed.

**Results**—More patients had  $\geq 70\%$  stenosis of the ipsilateral carotid artery 1 year after endovascular treatment than after endarterectomy (18.5% versus 5.2%,  $P=0.0001$ ). Residual severe stenosis was present in 6.5% of patients at 1 month after endovascular treatment. Between 1 month and 1 year, restenosis to  $\geq 70\%$  stenosis occurred in 10.5% of the endovascular group. After endarterectomy, 1.7% had residual severe stenosis at 1 month, and 2.5% developed severe restenosis. The results were significantly better after stenting compared with angioplasty alone at 1 month ( $P<0.001$ ) but not at 1 year. Recurrent ipsilateral symptoms were more common in endovascular patients with severe stenosis (5/32 [15.6%]) compared with lesser degrees of stenosis at 1 year (11/141 [7.8%],  $P=0.02$ ), but most were transient ischemic attacks and none were disabling or fatal strokes. There were no recurrent symptoms in the 9 endarterectomy patients with  $\geq 70\%$  stenosis at 1 year.

**Conclusions**—Carotid stenosis 1 year after endovascular treatment is partly explained by poor initial anatomical results and partly by restenosis. The majority of patients were treated by angioplasty without stenting. Further randomized studies are required to determine whether newer carotid stenting techniques are associated with a lower risk of restenosis. The low rate of recurrent stroke in both endovascular and endarterectomy patients suggests that treatment of restenosis should be limited to patients with recurrent symptoms, but long term follow up data are required. (*Stroke*. 2005;36:281-286.)

**Key Words:** angioplasty ■ carotid endarterectomy ■ carotid stenosis ■ ultrasonography, Doppler

The Carotid and Vertebral Artery Transluminal Angioplasty Study (CAVATAS) was the first large multicenter randomized clinical trial to compare percutaneous endovascular treatment (balloon angioplasty or stenting) with carotid endarterectomy for the treatment of atherosclerotic carotid artery stenosis.<sup>1</sup> Patient recruitment began in 1992 was completed in 1997, and the initial results showed similar risks of stroke or death within 30 days of endovascular treatment (10%) and endarterectomy (9.9%).<sup>1</sup> This complication rate was higher than desirable in both arms but was not significantly different from that recorded in the European Carotid Surgery trial and could have been the result of including

high-risk patients.<sup>1</sup> The 2 treatments appeared equally effective at preventing ipsilateral stroke for up to 3 years after randomization. However, the 95% confidence intervals surrounding the comparison of the hazards of each treatment were wide, and concerns about endovascular treatment of carotid stenosis remain. These include the possibility of technical failure to obtain a good initial result and the risk of vessel restenosis leading to recurrent symptoms.

Restenosis is well recognized after coronary angioplasty.<sup>2</sup> Case series of carotid endovascular treatment have reported an incidence of carotid restenosis/occlusion of between 5% and 14%.<sup>3–5</sup> Restenosis also occurs in up to 24% of patients

Received July 22, 2004; final revision received October 30, 2004; accepted November 8, 2004.

From the Stroke Research Group (D.J.H.M., A.C.P., M.M.B.), Institute of Neurology, University College London; the University Department of Clinical Neurosciences (D.J.H.M.), Royal Free and University College Medical School; the Departments of Neuroradiology (A.C.), and Neurology (A.C.P.), St. George's Hospital, London; and the Department of Health Sciences (J.M.B.), University of York, Heslington, York, UK

A list of the CAVATAS Investigators appears in the Appendix.

Correspondence to Prof Martin M. Brown, Box 6, The National Hospital for Neurology and Neurosurgery, Queen Square, London WC1N 3BG. E-mail m.brown@ion.ucl.ac.uk

© 2005 American Heart Association, Inc.

Stroke is available at <http://www.strokeaha.org>

DOI: 10.1161/01.STR.0000152333.75932.fe

after carotid endarterectomy.<sup>6</sup> An initial analysis of the ultrasound data from CAVATAS showed that severe stenosis or occlusion at 1 year follow-up was found in 18% of patients allocated to endovascular treatment compared with 5% of patients allocated to surgical treatment.<sup>1</sup> However, the angioplasty techniques used during the development of carotid endovascular treatment in CAVATAS did not always result in full dilation of the lesion.<sup>7</sup> Therefore, during the course of the study, we hypothesized that this measurement of stenosis at 1 year would include some patients who had residual severe stenosis secondary to initial inadequate dilation of the lesion and some with true restenosis over time. We also hypothesized that restenosis might lead to minor symptoms (eg, transient ischemic attacks [TIAs] from flow reduction) but not stroke. In the initial analysis, severe stenosis at 1 year did not appear to be associated with an increase in the rate of recurrent stroke, but we only included strokes lasting >7 days as specified by the protocol.<sup>1</sup> We therefore carried out a more detailed analysis of the Doppler ultrasound data from CAVATAS to determine the contribution of residual severe stenosis and restenosis to the overall stenosis rate at 1 year and to compare the results after carotid stenting with those after balloon angioplasty alone. We also assessed whether the risk of recurrent ipsilateral ischemic symptoms during early follow-up was influenced by the degree of carotid stenosis after treatment, to determine whether stenosis during follow-up should lead to reintervention.

## Methods

The design of CAVATAS has already been reported in detail.<sup>1</sup> In summary, patients with carotid stenosis suitable for both treatments were randomly allocated to undergo percutaneous endovascular treatment or carotid endarterectomy (surgery). Ninety percent of patients were symptomatic within 6 months of randomization, 7% had relevant symptoms >6 months before randomization, and 3% were completely asymptomatic. Demographic features were well matched in the 2 arms of the trial.<sup>1</sup> Initially, patients randomized to endovascular treatment were treated by percutaneous transluminal angioplasty using balloon catheters. Stents were subsequently allowed, but most were deployed as a secondary procedure after unsatisfactory initial balloon dilation. Wallstents, Palmaz and Strecker stents were used at the discretion of the treating radiologist. Overall, stenting was performed in 22% of those allocated endovascular treatment (26% of procedures).<sup>1</sup> The protocol specified that endovascular patients should be treated with aspirin or an alternative antiplatelet agent for at least 24 hours before the procedure and anticoagulated with intravenous heparin for at least 24 hours after the procedure. Carotid endarterectomy was performed by the technique routinely used by the collaborating surgeon. Perioperative shunts or patches were used in 64% and 63% of surgical procedures, respectively. All patients received antiplatelet therapy and treatment of vascular risk factors during follow-up, which was performed by an independent neurologist or stroke physician at 1 and 6 months, and then at yearly intervals after treatment. All outcome events, including TIAs, amaurosis fugax, and stroke were reported to the central office. The classification of these events was independently confirmed, blind to treatment received, by central and external review.

The ultrasound analysis presented in this article has been restricted to data obtained from centers where reliable facilities for ultrasound examination of randomized patients were available (see Appendix). In general, Doppler ultrasound examination of the carotid arteries was performed before randomization and at 1 year after treatment. Ultrasound was performed at 1 month after treatment in a smaller proportion of patients, but this was not required by the protocol because of budgetary constraints. The timing of the ultrasound

**TABLE 1. Velocity Criteria for Grading the Degree (%) of Carotid Stenosis on Doppler Ultrasound**

Stenosis (%)	PSV ICA (m/s)	EDV ICA (m/s)	PSV ICA/PSV CCA
0–29	<1.0	<0.4	<3.2
30–49	1.1–1.3	<0.4	<3.2
50–59	>1.3	<0.4	<3.2
60–69	>1.3	0.4–1.1	3.2–<4.0
70–79	>2.1	1.2–1.4	≥4.0
80–95	>2.1	>1.4	≥4.0
96–99	String Flow	String Flow	String Flow
100	Occluded	Occluded	Occluded

PSV indicates peak systolic velocity; ICA, internal carotid artery; EDV, end diastolic velocity; CCA, common carotid artery.

examination was calculated from the day of the procedure. However, because ultrasound examinations were not always performed exactly 1 month after treatment, we classified the ultrasound examination closest to 30 days after the procedure as the “1 month” ultrasound, so long as it was performed between 7 and 60 days after the procedure. Similarly, we classified the ultrasound examination closest to 360 days after treatment as the “1 year” ultrasound once it was performed between 181 and 540 days after treatment.

The clinical and Doppler ultrasound follow-up data were analyzed at the coordinating center. The degree of carotid stenosis was graded according to the velocity criteria outlined in Table 1. These criteria for grading carotid stenosis are identical to recently published criteria, with the exception that a peak systolic velocity (PSV) of >2.1 m/s, instead of 2.3 m/s, was used to identify an internal carotid artery (ICA) stenosis of ≥70%.<sup>8</sup> This PSV<sub>ICA</sub> measurement has been shown to have a sensitivity of 94.8% and a specificity of 78.6% in identifying an ICA stenosis of ≥70% using the North American Symptomatic Carotid Endarterectomy Trial (NASCET) method of grading ICA stenosis on digital subtraction angiography.<sup>9</sup> If the PSV<sub>ICA</sub>, end diastolic velocity (EDV<sub>ICA</sub>), or the ratio of the PSV in the ICA to that in the common carotid artery (CCA) spanned >1 stenosis category, 2 researchers reached a consensus on the carotid stenosis severity, with most emphasis placed on the PSV<sub>ICA</sub>. When velocity measurements were not available, the degree of carotid stenosis determined by the investigators at the participating center was used. Patients were subsequently categorized as having 1 of the following 4 grades of carotid stenosis: 0 to 49% (mild), 50 to 69% (moderate), 70 to 99% (severe), or 100% (occlusion).

The finding of stenosis during follow up could result from either a poor initial result from angioplasty or surgery (residual stenosis), or recurrence of stenosis after a good initial dilation or successful endarterectomy (restenosis). We defined residual severe stenosis as ≥70% carotid stenosis (or occlusion) at both the 1 month and 1 year ultrasound assessments. Restenosis was defined as the presence of <70% stenosis at 1 month, with subsequent development of severe carotid stenosis or occlusion at 1 year. Remodeling was defined as the presence of ≥70% stenosis at 1 month, with <70% carotid stenosis at 1 year.

To investigate whether the risk of experiencing recurrent symptoms during follow-up was influenced by the degree of carotid stenosis after treatment, only the patients who had an ultrasound examination performed at 1 year were included in the analysis. Recurrent symptoms were defined as ischemic cerebrovascular symptoms that occurred ipsilateral to the treated artery between 30 days after the randomized procedure and the date of last follow-up available at the time of analysis. We included TIA, amaurosis fugax, and both nonfatal and fatal ischemic stroke. Symptoms that occurred within 30 days after treatment were excluded from the analysis.

All data were analyzed on an intention-to-treat basis, except when comparing angioplasty with stenting, when on-treatment analysis was performed. The  $\chi^2$  test for trend or Fisher exact test were used for comparison of proportions between groups. The log-rank test was

**TABLE 2. Comparison of Carotid Stenosis Severity on Doppler Ultrasound Between the Endovascular and Surgery Groups**

Stenosis Severity	1-Month Measurements		1-Year Measurements	
	Endovascular (n=145)	Surgery (n=138)	Endovascular (n=173)	Surgery (n=174)
0–49%	102 (70.3%)	122 (88.4%)	104 (60.1%)	147 (84.5%)
50–69%	34 (23.4%)	12 (8.7%)	37 (21.4%)	18 (10.3%)
70–99%	8 (5.5%)	2 (1.4%)	25 (14.5%)	7 (4.0%)
100%	1 (0.7%)	2 (1.4%)	7 (4.0%)	2 (1.1%)

Values are No. of patients (%) with each category of stenosis. The overall differences between the endovascular and surgery groups are significant using the  $\chi^2$  test for trend at both 1 month ( $P=0.0007$ ) and 1 year ( $P<0.0001$ ).

used to compare the frequency of recurrent ipsilateral cerebrovascular symptoms between groups.  $P<0.05$  was considered statistically significant.

### Results

The 1 month ultrasound assessment was performed in 145 endovascular and 138 surgery patients at a mean of 35 days (range, 7 to 60 days) after treatment. The 1-year ultrasound assessment was performed in 173 endovascular and 174 surgery patients at a mean of 348 days (range, 181 to 524 days) after treatment. 124 endovascular patients and 118 surgery patients had an ultrasound examination performed at both 1 month and 1 year. The median duration of follow-up after randomization was 358 days (range, 181 to 2234 days) in the endovascular group and 363 days (range, 181 to 2152 days) in the surgery group.

In both groups, the ipsilateral median ICA stenosis severity before treatment was 70% to 99%. At both 1 month and 1 year after treatment, endovascular patients had significantly greater stenosis of the treated carotid artery than surgery patients (Table 2). Carotid occlusion at 1 year was more common in endovascular than surgery patients (4.0% versus 1.1%), but this difference was not statistically significant. Overall, 18.5% of endovascular patients compared with 5.1% of surgery patients had severe carotid stenosis or occlusion at 1 year ( $P=0.0001$ ).

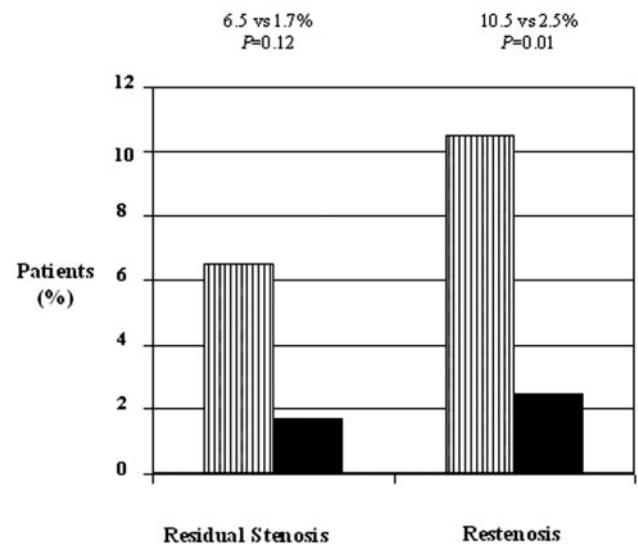
The rates of residual severe stenosis, restenosis, and remodeling were calculated using data from patients with ultrasound measurements at both 1 month and 1 year. In the endovascular group ( $n=124$ ), severe residual stenosis was present in 8 patients (6.5%) at 1 month, whereas restenosis from a lesser degree of stenosis at 1 month to severe stenosis at 1 year occurred in 13 patients (10.5%; Figure 1). Thus, residual severe stenosis, implying poor initial dilation of the lesion, was responsible for 8 of 21 (38%) endovascular patients who were found to have severe stenosis at 1 year. Restenosis occurring between the 1-month and the 1-year measurements was significantly more common in endovascular than surgery patients ( $P=0.01$ ; Figure 1). Remodeling of the treated carotid artery between 1 month and 1 year did not occur in the endovascular group and was seen in 2 (1.7%) surgery patients ( $P=0.47$ ).

The results of endovascular treatment at 1 month were significantly better in stented patients than in those treated with balloon angioplasty alone ( $P<0.001$ ; Figure 2A). A higher proportion of stented patients had mild or moderate stenosis, and there was a lower frequency of severe carotid

stenosis in the stented subgroup (2.5% versus 6.7%). No stented patient had carotid occlusion at 1 month. At 1 year, stented patients still tended to have a lower degree of carotid stenosis compared with the angioplasty alone subgroup, but this difference was not statistically significant ( $P=0.6$ ; Figure 2B).

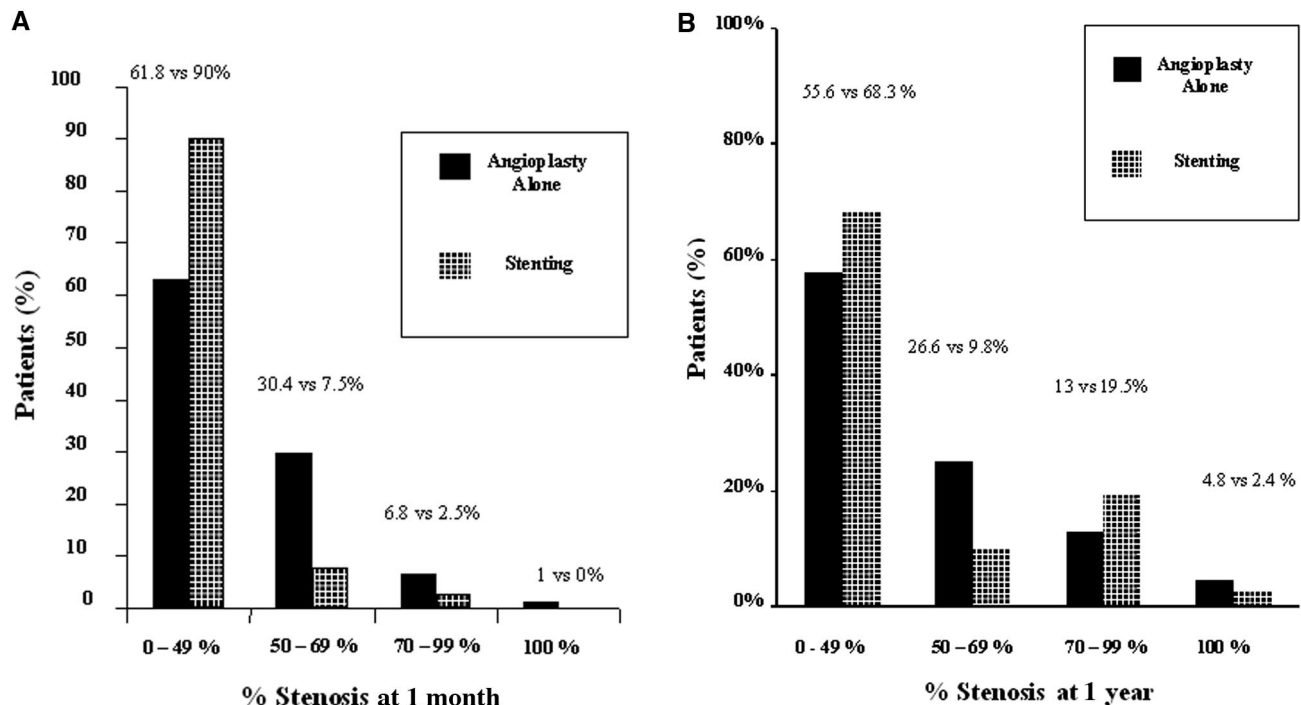
The results in the subgroup of endovascular patients treated with angioplasty alone were similar to the analysis of all of the endovascular patients combined. There was a significantly greater degree of carotid stenosis in the angioplasty alone patients than in those treated with surgery ( $P<0.0001$ ); 17.7% of the angioplasty alone subgroup versus 5.2% of surgery patients had  $\geq 70\%$  stenosis at 1 year. The degree of carotid stenosis was also greater at 1 year in stented than surgery patients ( $P=0.002$ ); severe carotid stenosis or occlusion was seen in 22% of stented patients versus 5.2% of surgery patients.

Among the endovascular patients with ultrasound measurements at 1 year, recurrent ipsilateral cerebrovascular symptoms during follow-up were significantly more common in patients with severe stenosis than those without severe stenosis (Table 3). Five of the 32 patients (15.6%) with  $\geq 70\%$  stenosis at 1 year were symptomatic compared with 11/141 patients (7.8%) with  $<70\%$  stenosis ( $P=0.02$ ). How-



**Figure 1.** Comparison of the proportion of patients with residual severe stenosis and restenosis on Doppler ultrasound of the ipsilateral carotid artery at 1 year in the endovascular (vertical black-striped bars;  $n=124$ ) and surgery (solid black bars;  $n=118$ ) groups.





**Figure 2.** A, Proportion of endovascular patients with different degrees of carotid stenosis on Doppler ultrasound in the angioplasty alone (n=102) and stented subgroups (n=40) 1 month after treatment. The differences between the angioplasty alone and stenting subgroups overall are significant ( $P<0.001$ ,  $\chi^2$  test for trend). B, Proportion of endovascular patients with different degrees of carotid stenosis on Doppler ultrasound in the angioplasty alone (n=124) and stented subgroups (n=41) 1 year after treatment. The differences between the subgroups overall are not significant ( $P=0.6$ ).

ever, most events that occurred in endovascular patients with severe stenosis were TIAs, and there were no disabling or fatal strokes during follow-up. There were no recurrent events in the 9 surgery patients with severe ipsilateral stenosis at 1 year, although recurrent ipsilateral symptoms occurred in 10/165 (6.1%) surgery patients with  $<70\%$  stenosis ( $P=0.5$ , Table 3).

### Discussion

CAVATAS is the first multicenter randomized trial to prospectively determine the degree of carotid stenosis during follow-up after both endovascular treatment and endarterectomy for symptomatic carotid stenosis. Our finding of a relatively low rate of severe carotid stenosis or occlusion at 1 month (2.8%) and 1 year (5.1%) after carotid endarterectomy, with a very low rate of recurrent symptoms related to surgical restenosis, is reassuring for patients undergoing surgical treatment.

In contrast to the results after surgery, endovascular treatment was associated with an incidence of severe stenosis or occlusion at 1 year of 18.5%. Analysis of the data from patients with ultrasound measurements at both 1 month and 1 year showed that poor early results, with residual severe stenosis at 1 month, accounted for more than one third of patients with severe stenosis after endovascular treatment at 1 year. This confirms that the high rate of stenosis at 1 year in CAVATAS was in part caused by poor initial results. These were almost certainly caused by the use of inferior techniques of balloon angioplasty during the early stages of development of carotid endovascular treatment in the trial. Initially, balloon angioplasty was performed using a 035 cerebral angiography wire and a standard 6-mm peripheral vascular balloon catheter. The stenosed artery was dilated to the estimated diameter of the normal ICA, but there was invariably subintimal dissection and some elastic recoil of the vessel wall after angioplasty. It was not until the latter half of the trial that

**TABLE 3. No. (%) of Patients Who Experienced Ipsilateral Ischemic Cerebrovascular Symptoms During Follow-Up in Association With  $<70\%$  or  $\geq 70\%$  Carotid Stenosis at 1 Year**

	Stenosis Severity	TIA/AF	RS	NDS	DS	FS	Total
Endovascular patients	$<70\%$ (n=141)	7 (5.0)	1 (0.7)	0	0	3 (2.1)	11 (7.8)
	$\geq 70\%$ (n=32)	4 (12.5)	0	1 (3.1)	0	0	5 (15.6)*
Surgery patients	$<70\%$ (n=165)	5 (3.0)	0	3 (1.8)	2 (1.2)	0	10 (6.1)
	$\geq 70\%$ (n=9)	0	0	0	0	0	0

TIA indicates transient ischemic attack; AF, amaurosis fugax; RS, recovered ipsilateral stroke lasting  $<7$  days; NDS, nondisabling stroke lasting  $>7$  days; DS, disabling stroke lasting  $>7$  days; FS, fatal stroke).

\* $P=0.02$  for comparison with endovascular patients with  $<70\%$  stenosis. No other difference was statistically significant.

stenting was performed in 22% of those allocated endovascular treatment, usually as a secondary procedure in patients with an initial poor result on the immediate postdilatation angiogram. It is possible that these early techniques led not only to poor technical results immediately after treatment but also to a higher rate of restenosis during follow-up secondary to neointimal or myointimal hyperplasia in response to excessive vessel dilation.

Our finding that stenting produced significantly superior results at 1 month after treatment compared with balloon angioplasty alone, supports current recommendations that stenting is the endovascular technique of choice for carotid stenosis. The finding that the superior anatomical results with stenting were no longer statistically significant at 1 year may reflect the small numbers of patients stented in CAVATAS but emphasizes the need for the ongoing randomized trials of carotid stenting to measure stenosis severity during follow-up. It has been suggested that ultrasound is not a satisfactory technique for determining restenosis after carotid stenting, because the difference in compliance between a stent and a native arterial wall could be responsible for an increase in the PSV, leading to an overestimation of the degree of stenosis in a stented artery.<sup>10</sup> Our finding that almost all stented patients who developed a severe increase in PSV did so between 1 month and 1 year makes it unlikely that our findings are artifactual and confirms the value of ultrasound follow-up after carotid stenting.

The risk of recurrent ipsilateral cerebrovascular symptoms distal to an untreated atherosclerotic carotid artery is directly proportional to the severity of the stenosis.<sup>11–14</sup> In contrast, case series of carotid endovascular treatment have shown that although restenosis may occasionally cause recurrent symptoms, most patients with moderate or severe stenosis after treatment remain asymptomatic at least in the first few years after treatment.<sup>3–5,15–17</sup> Our results support these findings, but we have also shown that the proportion of patients experiencing recurrent ischemic symptoms is significantly increased in patients with  $\geq 70\%$  stenosis at 1 year after endovascular treatment. However, most symptoms that occurred in association with  $\geq 70\%$  stenosis in the endovascular group were TIAs; no patient in this stenosis category had a disabling or fatal stroke during follow-up. This low frequency of symptoms can be explained by the finding that carotid restenosis early after treatment is usually secondary to myointimal hyperplasia rather than recurrent atherosclerosis.<sup>6,18,19</sup> Myointimal hyperplasia results in a smooth endoluminal surface, with a lower propensity to undergo ulceration or produce turbulent blood flow and subsequent distal thromboembolism than primary atherosclerotic stenosis. When symptoms occur, they are more likely to be flow-related hemodynamic TIAs.<sup>18</sup> Nevertheless, one must be cautious about concluding that restenosis after endovascular treatment is benign, because of the limited number of outcome events and the relatively short period of follow-up analyzed to date. We are therefore continuing clinical and Doppler ultrasound follow-up of patients in CAVATAS. In the meantime, it is reassuring that recurrent symptoms were very infrequent in the 2 treatment groups, despite the finding of severe carotid stenosis or occlusion in 18.5% and 5.1% of endovascular and

surgery patients, respectively. We therefore recommend that treatment for restenosis is limited to patients with recurrent symptoms.

Over the past few years, carotid endovascular techniques have been markedly refined with the availability of wires and stents that are specifically designed for the carotid artery, and it is likely that these modifications will improve the efficacy and reduce the risks associated with treatment in future.<sup>20</sup> However, it remains uncertain whether improved technology will improve the rate of restenosis. It is therefore essential that further long-term data should be obtained from ongoing prospective randomized controlled trials comparing newer techniques of carotid stenting with endarterectomy.

## Appendix

### CAVATAS Collaborators

Organizing Committee: J.M. Bland, M.M. Brown (principal investigator), T. Buckenham, A. Clifton, P.A.G. Sandercock, R.S. Taylor  
Data Monitoring Committee: R. Collins, G. Tognoni, C.P. Warlow (chairman)

Trial Statistician: J.M. Bland

Trial Offices, St George's Hospital Medical and Institute of Neurology, University College London, UK: T. Bleakley, D. Colquhoun, L. Coward, F. Crawley, P. Dobinson, R. Featherstone, S. Holder, H. Markus, D.J.H. McCabe, A. Pereira, J. Rogers, L. Silver

Clinical Trial Service Unit, Oxford, UK: J. Burrett, J. Crowther, M. Dobson, B. Hafner, J. Heineman, C. Hope, S. Knight, A. Naughten, A. Radley, S. Richards, D. Smith, S. Wenzel

Clinical Audit Committee: M. Harrison, J. Ferro

Credentials Committee: J. Beard, T. Buckenham, M.M. Brown, A. Clifton.

CAVATAS Centres and other collaborators

The following investigators contributed to CAVATAS at centers providing ultrasound data and had the opportunity to comment on the draft manuscript.

Australia: Austin and Repatriation Medical Centre, Heidelberg (C.F. Bladin, G.A. Donnan, G. Fell, G. Fitt, J. Royle); Royal Melbourne Hospital (S. Davis, R. Gerraty, P. Mitchell); Royal Perth Hospital (M.A. Goodman, G.J. Hankey, M.S. Khangure, M.M. Lawrence-Brown, J. Linto, W. McAuliffe, F.J. Prendergast, K. Siennarine, E.G. Stewart-Wynne)

Canada: Ottawa General Hospital (S. Grahovac, W. Morrish, N. Pageau, C.E. Pringle, D.M. Richard)

Germany: Heinrich Heine University, Duesseldorf (J. Malms, L. Reiher, M. Siebler); Magdeburg University Hospital, Germany (M. Goertler)

United Kingdom: Atkinson Morley's and St George's Hospitals, London (M.M. Brown, T. Buckenham, A. Clifton, D. Colquhoun, F. Crawley, P.W. Leopold, T. Loosemore, D.J.H. McCabe, A.C. Pereira, J. Rogers, R.S. Taylor); Gloucestershire Royal Hospital (P.A. Birch, J.J. Earnshaw, G.N. Fuller, B. Heather, K. Poskitt, A.J. Tottle); Kings College Hospital, London (P. Baskerville, T. Cox, S. Fraser, M. Jeffrey, L. Kalra, H. Markus, J. Molloy); Newcastle General Hospital (A. Gholkar, A.D. Mendelow, T.J. Walls); Queen Elizabeth Neuroscience Centre, Birmingham (M. Duddy, M.T.E. Heafield, R.K. Vohra); Queens Medical Centre, Nottingham (D.T. Hope, D. Jefferson, N. McConachie); Royal Hallamshire and Northern General Hospitals, Sheffield (J.D. Beard, T.J. Cleveland, C. Doyle, P.A. Gaines, A. Sivaguru, G.S. Venables); Royal London Hospital, London (P. Butler, J. Dick, F. Frankel); University Hospital of Wales, Cardiff (H. Angus-Leppan, S. Halpin, J. Hughes, I. Lane, M. Wiles, A.M. Wood); Walton Centre, Liverpool (T.P. Enevoldson, G. Gilling-Smith, P. Harris, T. Nixon); Western General Hospital, Edinburgh (A. Bradbury, D. Collie, J.A. Murie, C.V. Ruckley, P.A.G. Sandercock, D. Schultz, R.J. Sellar, J. Wardlaw); Withington Hospital, Manchester (R.J. Ashleigh, C.N. McCollum, P. O'Neill)

Italy: Policlinico St Marco, Bergamo-Zingonia (G. Belloni, M. Porta)

Spain: Hospital Clinic I Provincial, Barcelona (A. Chamorro, N. Vila [deceased], V. Rimbau, F. Vasquez); Hospital Universitario Virgen del Rocío, Sevilla (F. Boza, J.L. García Rodríguez, A. Gil Peralta, A. González, J.R. González Marcos, A. Mayol Deya, J. Rauno)

Switzerland: Centre Hospitalier Universitaire Vaudois, Lausanne (J. Bogousslavsky, A. Uske); University Hospital, Basel (E.C. Kirch, Ph.A. Lyrer, J.A. Rem)

## Acknowledgments

D.J.H.M. was funded by a grant from the Brain Research Trust. Chair in Stroke Medicine for M.M.B is supported by The Reta Lila Weston Trust. CAVATAS was funded by grants from the British Heart Foundation, the National Health Service Management Executive, and the Stroke Association. The ultrasound laboratory at the central trial office was funded by the Wellcome Trust and the Neurosciences Research Foundation.

## References

1. CAVATAS investigators. Endovascular versus surgical treatment in patients with carotid stenosis in the Carotid and Vertebral Artery Transluminal Angioplasty Study (CAVATAS): a randomized trial. *Lancet*. 2001;357:1729–1737.
2. RITA Trial Participants. Coronary angioplasty versus coronary artery bypass surgery: the Randomized Intervention Treatment of Angina (RITA) Trial. *Lancet*. 1993;341:573–580.
3. Yadav JS, Roubin GS, Iyer S, Vitek J, King P, Jordan WD, Fisher WS. Elective stenting of the extracranial carotid arteries. *Circulation*. 1997;95:376–381.
4. Gil-Peralta A, Mayol A, Gonzalez Marcos JR, Gonzalez A, Ruano J, Boza F, Duran F. Percutaneous transluminal angioplasty of the symptomatic atherosclerotic carotid arteries: results, complications and follow-up. *Stroke*. 1996;27:2271–2273.
5. Teitelbaum GP, Lefkowitz MA, Giannotta SL. Carotid angioplasty and stenting in high-risk patients. *Surg Neurol*. 1998;50:300–312.
6. Bernstein EF, Torem S, Dilley RB. Does carotid restenosis predict an increased risk of late symptoms, stroke, or death? *Ann Surg*. 1990;212:629–636.
7. Crawley F, Clifton A, Markus H, Brown MM. Delayed improvement in carotid artery diameter after carotid angioplasty. *Stroke*. 1997;28:574–579.
8. Sidhu PS, Allan PL. Ultrasound assessment of internal carotid artery stenosis. *Clin Radiol*. 1997;52:654–658.
9. Moneta GL, Edwards JM, Chitwood RW, Taylor LM, Lee RW, Cummings CA, Porter JM. Correlation of North American Symptomatic Carotid Endarterectomy Trial (NASCET) angiographic definition of 70% to 99% internal carotid artery stenosis with duplex scanning. *J Vasc Surg*. 1993;17:152–159.
10. Robbin ML, Lockhart ME, Weber TM, Vitek JJ, Smith JK, Yadav J, Mathur A, Iyer SS, Roubin GS. Carotid artery stents: early and intermediate follow-up with Doppler US. *Radiology*. 1997;295:749–756.
11. North American Symptomatic Carotid Endarterectomy Trial Collaborators. Beneficial effect of carotid endarterectomy in symptomatic patients with high-grade carotid stenosis. *N Engl J Med*. 1991;325:445–453.
12. European Surgery Trialists' Collaborative Group. Endarterectomy for moderate symptomatic carotid stenosis: interim results from the MRC European Carotid Surgery Trial. *Lancet*. 1996;347:1591–1593.
13. European Surgery Trialists' Collaborative Group. Randomized trial of endarterectomy for recently symptomatic carotid stenosis: final results of the MRC European Carotid Surgery Trial (ECST). *Lancet*. 1998;351:1379–1387.
14. Barnett HJM, Taylor DW, Eliasziw M, Fox AJ, Ferguson GG, Haynes RB, Rankin RN, Clagett GP, Hachinski VC, Sackett DL, Thorpe KE, Meldrum HE for the North American Symptomatic Carotid Endarterectomy Trial Collaborators. Benefit of carotid endarterectomy in patients with symptomatic moderate or severe stenosis. *N Engl J Med*. 1998;339:1415–1425.
15. Eckert B, Zanella FE, Thie A, Steinmetz J, Zeumer H. Angioplasty of the internal carotid artery: results, complications and follow-up in 61 cases. *Cerebrovasc Dis*. 1996;6:97–105.
16. Schoser BG, Becker VU, Eckert B, Zeumer H, Thie A. Clinical and ultrasonic long-term results of percutaneous transluminal carotid angioplasty: a prospective follow-up of 30 carotid angioplasties. *Cerebrovasc Dis*. 1998;8:38–41.
17. Porta M, Munari LM, Belloni G, Moschini L, Bonaldi G. Percutaneous angioplasty of atherosclerotic carotid arteries. *Cerebrovasc Dis*. 1991;1:265–272.
18. Crawley F, Clifton A, Taylor RS, Brown MM. Symptomatic restenosis after carotid percutaneous transluminal angioplasty. *Lancet*. 1998;352:708.
19. Terada T, Tsuura M, Masuo O, Matsumoto H, Yamaga H, Yokote H, Nakai K, Itakura T. Treatment of restenosis after percutaneous transluminal angioplasty for internal carotid artery stenosis. *Neuroradiology*. 2000;42:296–301.
20. Gaines PA. Carotid angioplasty and stenting. *Br Med Bull*. 2000;56:549–556.